

7TH EUROPEAN

CONGRESS

OF SURGERY

EUROSURGERY '97

ASTIR PALACE HOTEL

ATHENS

3-7 JUNE 1997

FINAL PROGRAMME

UNDER THE AUSPICES OF THE PRESIDENT
OF THE REPUBLIC OF GREECE, THE HONORABLE
Mr Konstantinos Stefanopoulos

CHAIRMAN OF THE ORGANISING COMMITTEE
Professor I.K. Poulantzas

AEGIS ACKNOWLEDGEMENT
Mayor of Athens
Mr. D. Avramopoulos



CONGRESS ORGANISERS SECRETARIAT

OPTIONS EUROCONGRESS LTD • c/o 129, Rue Washington • 1050 Brussels • Belgium

Tel: + 32 2 346 5301/5641 • Fax: + 32 2 346 5415/3617

brachial index <0.9 were excluded. Limbs were classified in seven categories according to CEAP classification.

Results: The most common location of reflux was seen in the SSV in 115 (87 per cent) limbs, followed by the saphenopopliteal junction (SPJ) in 84 (64 per cent), the GVs in 50 (38 per cent) and the Giacomini vein in 42 (32 per cent). Reflux confined to superficial tributaries five (4 per cent) or to GVs alone six (5 per cent) was rare. Fifty-seven incompetent perforating veins were found in 38 limbs, most often seen at the posterior midcalf 39 (68 per cent) and the posterolateral lower calf and ankle 15 (26 per cent). The most common clinical presentation was varicose veins in 102 limbs (77 per cent), followed by swelling 46 (35 per cent) and skin changes 26 (20 per cent). Active or healed ulceration was only observed in nine (7 per cent). Symptoms such as aching, itching, heaviness, and burning sensation were present in 49 limbs (37 per cent). Worsening symptoms were related to the extent of reflux and the presence of perforator incompetence.

Conclusions: The main trunk of SSV is most commonly involved and often reflux exists in this vein in the absence of SPJ incompetence. Our findings suggest that clinical deterioration is associated with increasing extent of reflux and perforator incompetence. Although swelling and skin changes are commonly seen in these patients, ulceration is rare. The variable patterns of reflux and the complex anatomy of the SSV system, particularly the variations in the SSV termination reinforce our belief that the use of colour flow duplex imaging before planning treatment is essential.

Composition of carotid plaque as a predictor of outcome of carotid endarterectomy

C. Liapis¹, V. Papavassiliou¹, K. Koumakis³, C. Verykokos¹, J. Papachristos¹, C. Ionidis¹, E. Evangelidakis¹, A. Gougoulakis², N. Kavantzias⁴, E. Agapitos⁴, P. Savaris⁴ and M. Sechas²
¹2nd Department of Prop. Surgery, Athens University, ²3rd Department of Surgery, Athens University, ³Neurology Department, Laiko Hospital, ⁴Department of Pathology, Athens University, Greece

Aim: To estimate the percentage of the carotid atherosclerotic plaque components using image analysis as well as to search for a probable correlation with the neurological status of the patients.

Material and methods: There were 50 patients who underwent a carotid endarterectomy. According to their preoperative neurologic status, the patients were classified as asymptomatic (Group I, n=20), symptomatic-TIA (Group II, n=14) and symptomatic-previous stroke (Group III, n=16). To determine the carotid artery stenosis, digital-subtraction angiography and colour duplex scanning were used. The surgical samples were histologically examined. For the image analysis and the exact estimation of the carotid plaque components, special algorithms were developed. The statistical evaluation was performed using one-way analysis of variance (ANOVA).

Results:

| | Neurologic groups | | | ANOVA | |
|------------------------|-------------------|--------|--------|--------|--------|
| | I | II | III | F | P |
| Fibrous component | 86.45% | 87.11% | 88.62% | 0.2228 | 0.8010 |
| Calcium | 2.97% | 2.14% | 3.84% | 1.0471 | 0.3589 |
| Cellular infiltrations | 4.27% | 4.14% | 2.97% | 0.2879 | 0.7510 |
| Cholesterol | 3.95% | 5.57% | 3.50% | 0.3549 | 0.7030 |
| Haemorrhage | 2.35% | 0.96% | 0.68% | 1.8805 | 0.1638 |

Between the groups I-III, there was not found any statistically significant difference of all the estimated parameters.

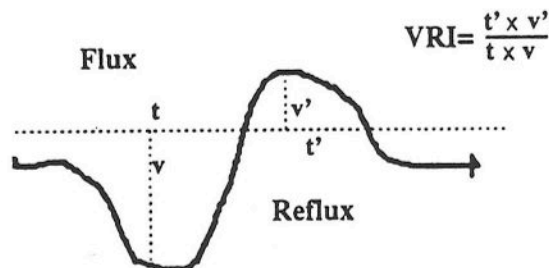
Conclusions: The morphology of the carotid atheromatous plaque seems not to be correlated with the preoperative neurologic status of the patients. The image analysis is an important, accurate and reproducible method for the unbiased measurement of the carotid atherosclerotic plaque components.

Normal range for venous index in lower limbs

S. Molski, M. Thews and Z. Mackiewicz
 Department of General and Vascular Surgery, University School of Medical Sciences, Skłodowskiej Curie 9, 85094 Bydgoszcz, Poland

The main qualifying criterion for reconstructive operations is estimation of haemodynamic changes in deep venous system. Hitherto existing methods, both invasive and noninvasive, are not fully satisfactory. Recently the duplex scan was introduced to venous haemodynamic estimation.

The aim of the study was to establish normal and pathological ranges on the basis of venous reflux index (VRI) in duplex scan examinations. Twenty-one patients without any pathological changes in the lower limb's venous system were included to the study. There were 14 women, mean age 29.9 years (range 17-57) and seven men, mean age 33.9 years (range 27-57). Forty-two limbs were examined and VRI in femoral and popliteal veins were calculated by the following formula:



Results in the examined groups are: VRI for popliteal vein=0.285±0.157, VRI for femoral vein=0.300±0.242. The above presented results enabled us to establish a normal range for venous reflux index on the level of popliteal and femoral veins. The described method can be very useful in estimating of normalization of venous circulation after the reconstructive operations upon the lower limb's venous system.

Microembolic signals in carotid endarterectomy

M. Müller, P. Walter¹, S. Behnke, V. Dzindzibadze and G. Feifel¹
 Department of Neurology and ¹Surgery, University Hospital of the Saarland, Oscar-Orth Str., D-66412 Homburg/Saar, Germany

In carotid endarterectomy (CEA) microembolism may be a major cause of intraoperative stroke. Intraoperative transcranial Doppler ultrasound (TCD) recordings may help to differentiate between strokes due to haemodynamic ischaemia after clamping or to microembolism.

Material and methods: Seventy-nine CEAs in 75 patients (61 men, 14 women, mean age 63±10 years) were monitored by means of TCD from skin incision to wound closure. A mean blood velocity decrease of ≥70 per cent after clamping, as compared to the preclamping level, was used to indicate shunting. Microembolic signals (MES) were counted on the whole procedure by postoperative videotape analysis. According to the European Carotid Surgery Trial method the mean degree of the carotid stenoses was 82 per cent (range 53-97 per cent). Fifty-four stenoses were symptomatic and 27 asymptomatic. Each patient was examined by a neurologist preoperatively and within 6h postoperatively. Any new neurological deficit at postoperative examination was considered an intraoperative stroke when persisting for more than 24h. Each patient received a cranial computed tomography on Day 3-5 after CEA.

Results: MES were present in all but one CEA. Of eight strokes only five were recognized by the surgical team. Five strokes showed new corresponding territory infarcts on CT scans, in the three remaining cases MES were present. No patient with stroke suffered from haemodynamic ischaemia after clamping. CEAs with strokes showed significantly more MES (median 33; range 11-159) than those without strokes (10; range 0-79; P=0.002). In the presence of ≥11 MES (42 CEAs) the relative risk to suffer from stroke was 1.23 (95 per cent confidence interval, 1.06-1.43) as compared to the CEAs with ≤10 MES (no stroke in 37